

Left Ventricular Hypertrophy in a College Athlete: Physiological or Pathological?

Prashant Rao, Max Weiss, Drew Johnson, Rob Bloom, Aneil Malhotra, David Shipon

Division of Cardiovascular Medicine, Department of Medicine, Thomas Jefferson University Hospital, Philadelphia, PA, USA

Background

The differentiation of 'athlete's heart' from morphologically mild hypertrophic cardiomyopathy (HCM) is important as an erroneous diagnosis can lead to the catastrophic event of sudden cardiac death.

Conversely, an athlete with physiological adaptation may be unnecessarily restricted.

Case

A 20-year-old African-American male college athlete (track/basketball) presented with near-syncope during intense exercise. There was no significant past medical or family history.

Electrocardiogram revealed LVH by voltage criteria (Sokolow-Lyon) and deep T-wave inversion in the inferior and lateral leads.

Echocardiography showed diffuse concentric LVH (maximal wall thickness: 16mm; relative wall thickness 0.65), LV mass 285.45g, LVIDd 4.3cm, normal left atrial size, normal LV filling and hyperdynamic EF of 83%. There was no outflow tract obstruction during exercise.

LVEDV on cardiac MRI was 106ml with findings reported as 'borderline for athlete's heart'. Post contrast imaging did not demonstrate delayed myocardial enhancement.

An implantable loop recorder did not reveal any arrhythmias and genetic testing did not show any mutations consistent with hypertrophic cardiomyopathy.

Figure 1: ECG

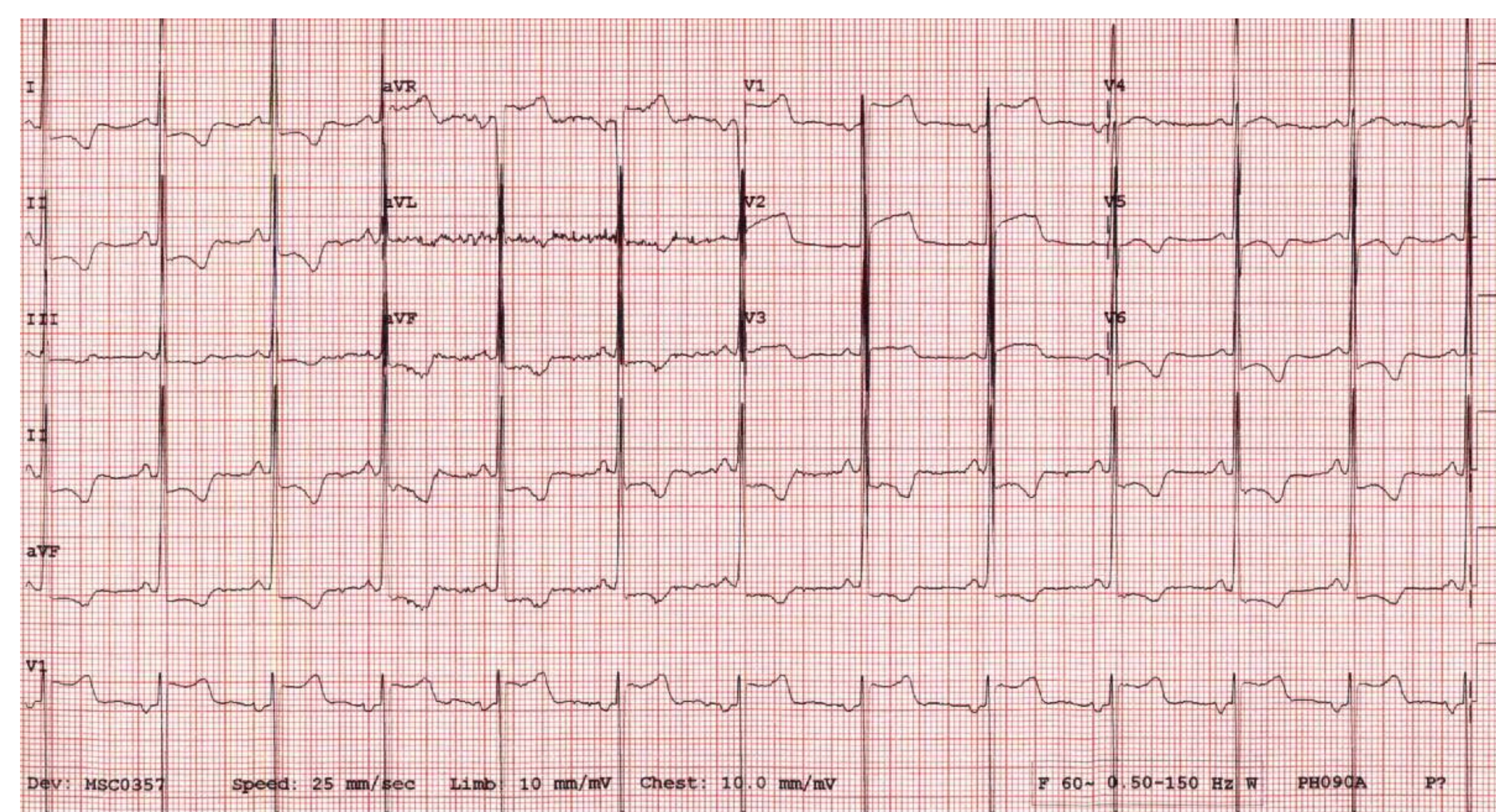


Figure 2: Echocardiography

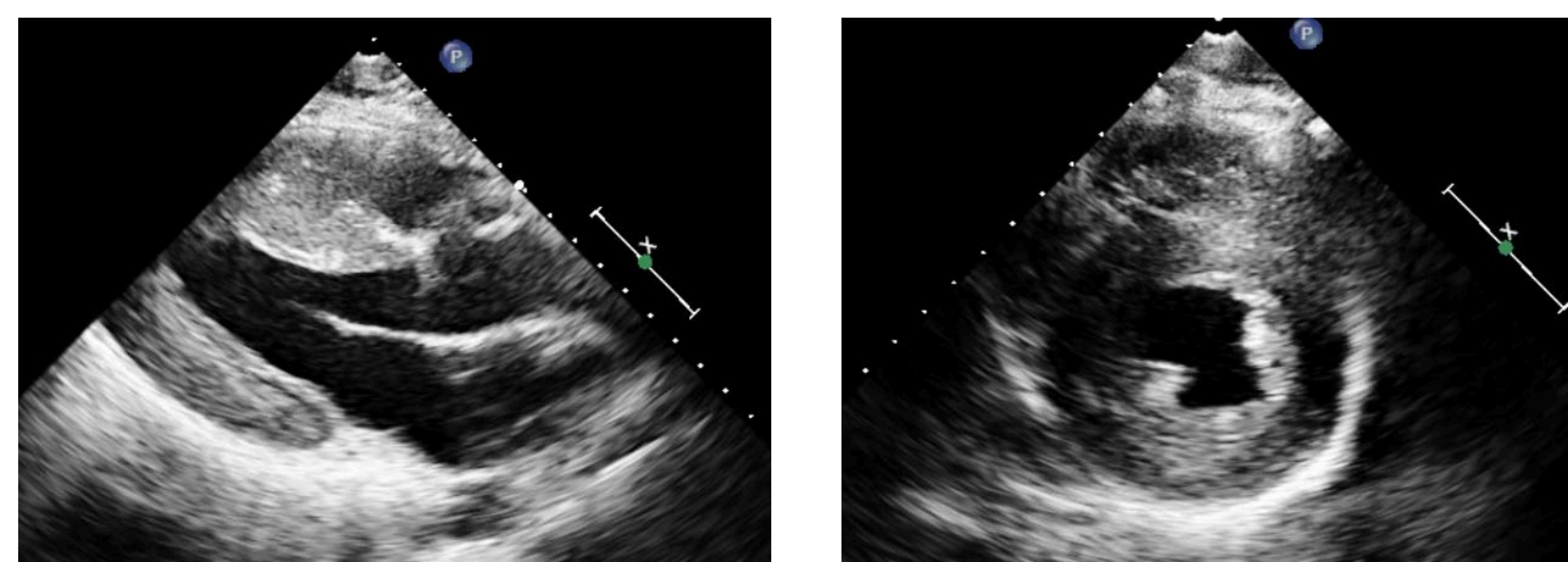
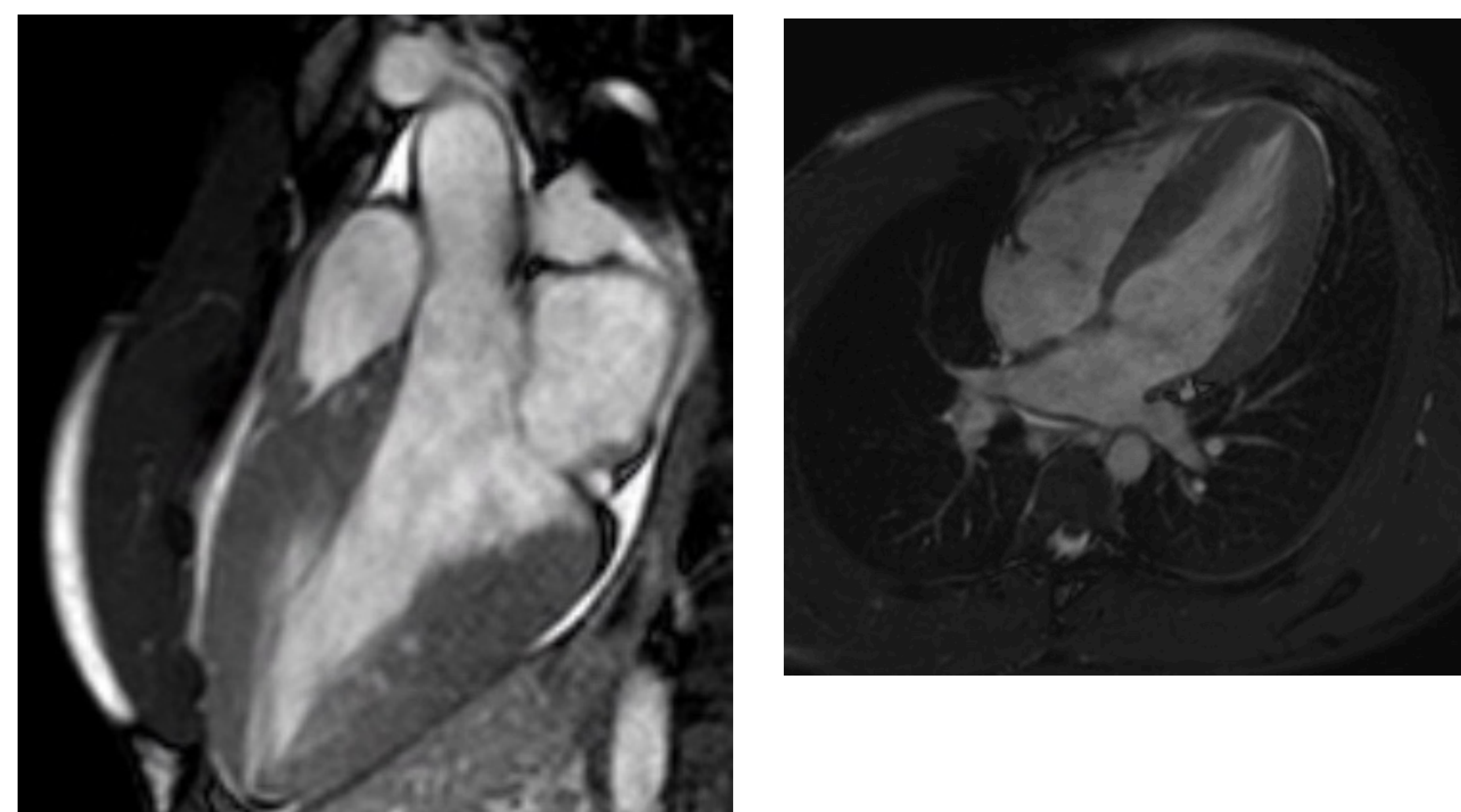


Figure 3: MRI

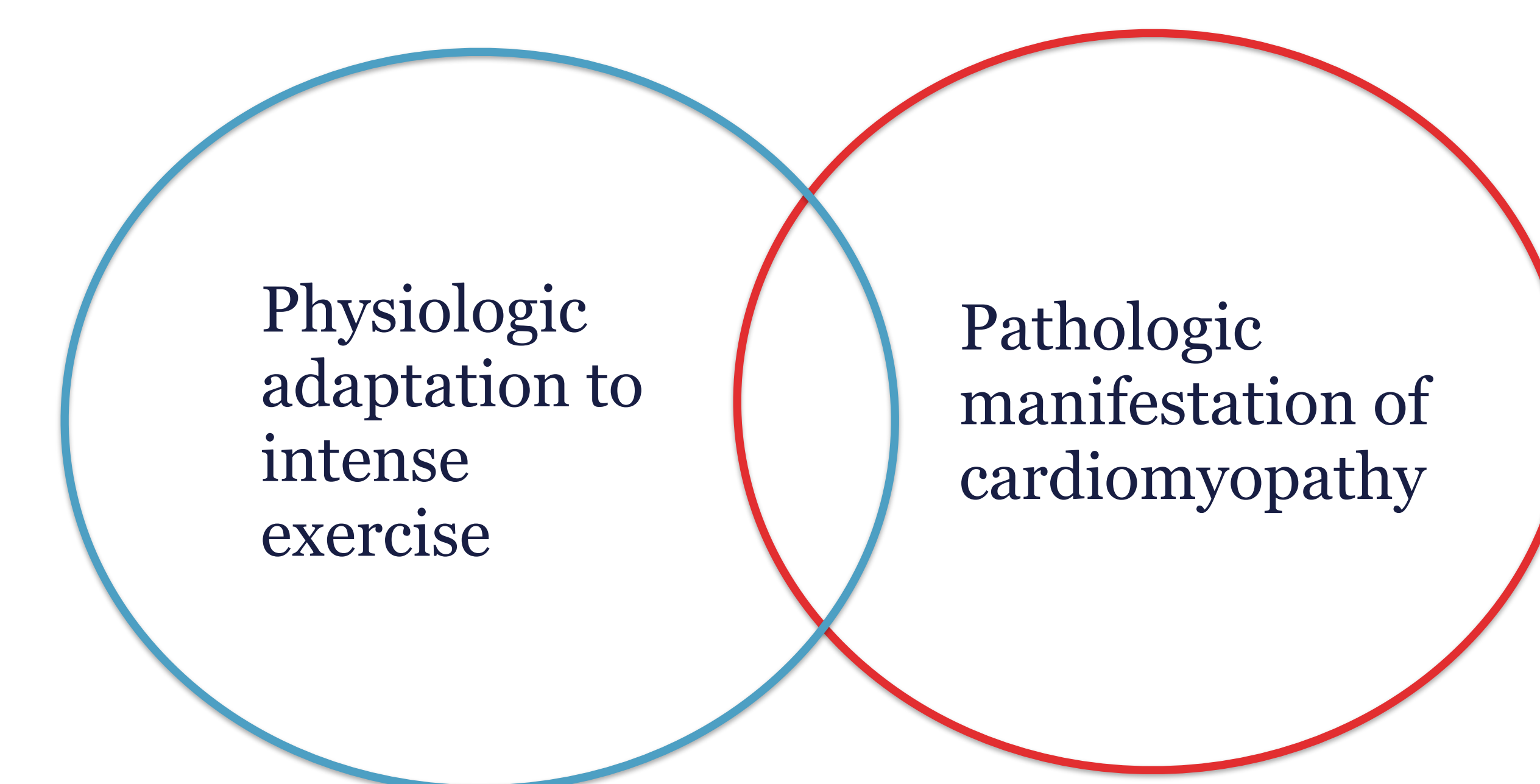


Decision-Making

The diagnosis of HCM was favoured over athlete's heart due to the abnormal electrocardiographic findings with a small LV cavity (<45mm). The diagnosis of HCM was further corroborated by repeat echocardiography after exercise restriction showed no change in LV thickness, with new discrete upper septal thickening.

Conclusion

The diagnosis of HCM in athletes is challenging but important to reduce the risk of sudden cardiac death in this at-risk population.



Key factors to discriminate between athlete's heart vs HCM

- Cardiovascular Symptoms
- Family History for HCM/SCD
- Major ECG abnormalities
- Asymmetric pattern of LVH
- Normal/Reduced LVIDd (<54mm)
- LV outflow obstruction/SAM
- Abnormal diastology
- No reduction in wall thickness with detraining

(Less helpful is exercise performance and LA size)